

Medical reports on clinical uses of CLINY Ileus Tube

①A 66 year old patient who was treated with a CLINY Ileus Tube

The patient was hospitalized from May 22, 2003 to June 16, 2003 in our department of surgery.

Diagnoses.:

1. Re-occurrence of ileus caused by abdominal adhesions
2. Condition of site where appendectomy was performed 40 years ago
3. Condition of site where ileus operation of partial resection of the colon was performed 20 years ago
4. No-torsion of the duodenum

Our treatment policy:

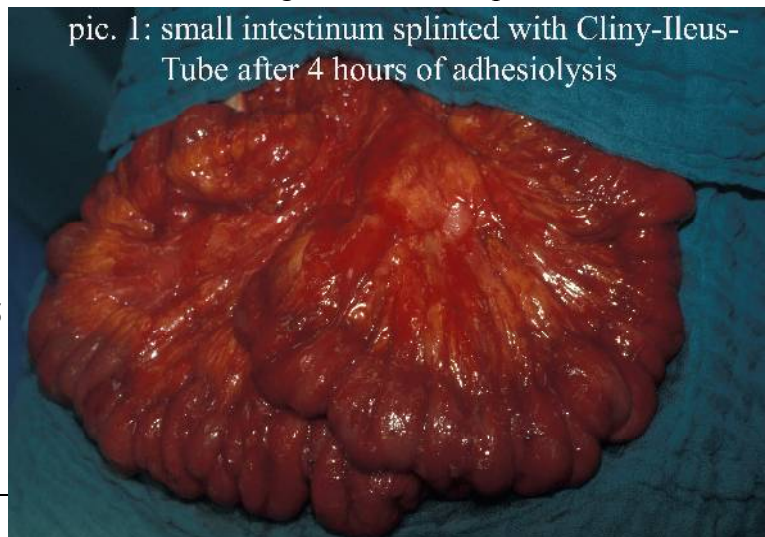1. extensive enterolysis
2. partial resection of small bowel
3. intra-operative splinting of small bowel with a CLINY Ileus Tube

Epicrisis:

A 66 year old male patient with an adhesion ileus came in our emergency admission. Appendectomy was performed to the patient more than 40 years ago. Ileus operation was also performed 20 years ago. In recent years he had signs of recurrent ileus which made clinical treatment necessary.

In a 4 hours operation, we did an extensive enterolysis and a partial resection of small bowel.

During the operation, torsion of the duodenum was not diagnosed. In the operation, CLINY Ileus Tube was inserted transnasally by the anaesthetist and it was pushed further until the cecum with surgical assistance. Aspiration was made during the insertion. The balloon of CLINY Ileus tube was inflated with 25 ml distilled water for blocking the inner cecum.



(picture 1: the splinted bowel before replacement in the abdomen).

The splinted small bowel by CLINY Ileus Tube was repositioned in the abdomen with a Noble's like procedure.

The block was released after 12 hours from the operation.

Abdominal X-ray photo was taken on the 1st day after the operation(picture 2: splinted small bowel).

The patient agreed with the use of CLINY Ileus Tube in the operation.

At the 4th day after insertion of CLINY Ileus Tube, we begun to remove the tube aprox. 20cm every day. When the tube was left 70cm in the patient, we removed the tube completely.

In a postoperative process the patient had singultus on the first day. And He was not able to get his usual food for the 10th days after the operation as he involved in a mobility disturbance of the intestine struck.

In the following days the patient could be discharged as a regular intestinal passage was confirmed.

②A 67 year old man who was treated with a CLINY Ileus Tube.

Diagnoses:

- 1. Advanced mechanical ileus by incarcerated Jejunum and resulted paralysis of the whole small bowel**
- 2. Haemorrhagic erosive enterocolitis with gastrointestinal bleeding**
- 3. Situation of 6 days after kidney transplantation**
- 4. Situation after terminal renal insufficiency due to an IgA-nephritis and a diabetic nephropathia**
- 5. Diabetes mellitus**

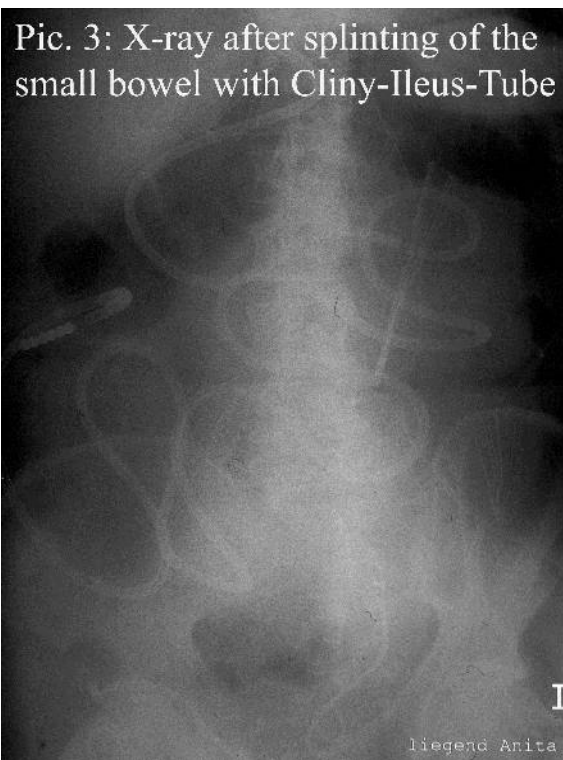
Our treatment policy:

- 1. Laparotomy with reposition of the incarcerated small bowel loop**
- 2. Aspiration and splinting of the small bowel with a CLINY Ileus Tube**

Epicrisis:

A 67 year old male patient had developed the clinical signs of a paralytic ileus on the 6th postoperative day after kidney transplantation with terminal renal insufficiency due to an IgA-nephritis and diabetic nephropathie during his stay at the intensive-care-unit. In the following explorative relaparotomy, 5cm dehiscence of the fascia and peritoneum was done and an incarceration of jejunal loop itself was confirmed as the reason for his symptoms. A paralysis of the whole small bowel was demonstrated. After reposition of the bowel by the surgeon, a transnasal insertion of the Cliny Ileus Tube with its guidewire was done by the anaesthetist. The Cliny Ileus Tube was pushed into the cecum after passing the stomach, duodenum and the rest of the small bowel by surgical assistance and the balloon of CLINY Ileus tube was inflated with 25 ml distilled water for blocking the cecum. After emptying the small bowel by aspirating with the CLINY Ileus Tube, Noble's procedure was made to the splinting small bowel, and then repositioned in the abdomen.

24 hours later the blocking with balloon was released and abdominal X-ray photo was taken (picture 3).



Pic. 3: X-ray after splinting of the small bowel with Cliny-Ileus-Tube

On the 4th day after insertion of the CLINY Ileus Tube, it was extracted by few cm every few hours. On the 6th day after insertion of the CLINY Ileus tube, an upper gastrointestinal bleeding was found, and therefore CLINY Ileus Tube was completely extracted during gastroscopy examination. With continuous loss of gastrointestinal blood, the patient got first an embolisation of the A. gastroduodenalis, and finally in a further relaparotomy, a jejunal ulcer was oversewed at a haemorrhagic erosive enterocolitis caused by CMV. In the whole time, the patient stayed at the intensiv-care-unit and he got parenteral feeding. The immunological suppressed patient died in the following days.

③A 64 years old male patient who was treated with a Cliny Ileus Tube

The patient was hospitalized from February 20, 2004 to March 2, 2004 in our department of surgery.

- Diagnoses:**
- 1. Incarcerated hernia of the small intestine with fused bowels**
 - 2. Situation after resection of the sigmoid**
 - 3. Chronical cholecystitis**
 - 4. Tachyarrhythmia absoluta**

Our treatment policy:

- 1. Complete adhesiolysis with explorative laparotomy.**
- 2. Releaf and splinting of the small bowel with the CLINY Ileus Tube placed during the operation**
- 3. Plastical closure of the abdominal wall**
- 4. Cholecystectomy**

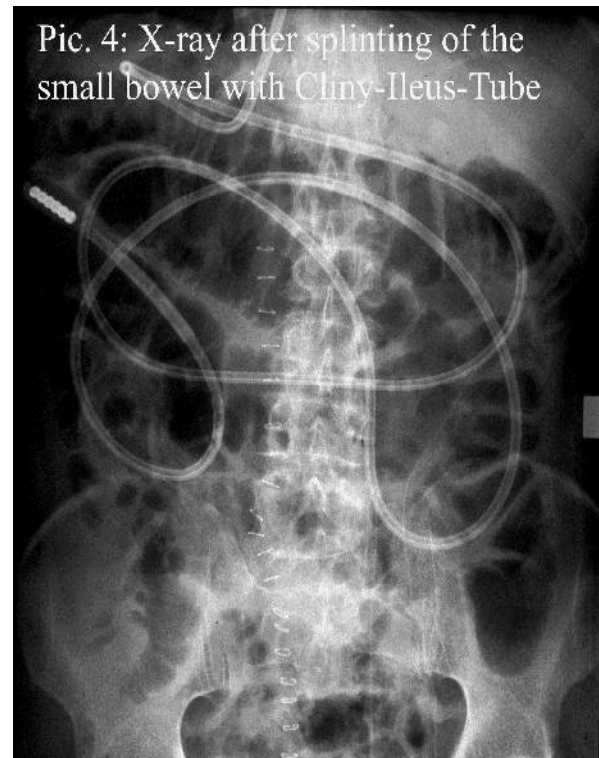
Epicrisis:

The 64 years old patient came to us with colic-like pain of the bowel, nausea and vomitus. He told us that there had been no defecation for 4 days. In the clinical examination the patient had a significant meteorism. We further examined and found that a resection of the sigmoid was performed several years ago.

A conventional radiograph of the bowel showed an ileus of the small bowel with several endoluminal surfaces. In a radiophague-enhanced CT we saw distended, obstructed bowels of the small bowel with surfaces which matches a situation of ileus. No tumor was seen, which could have been blamed to cause the ileus. On the February 20, 2004 we performed an explorative laparotomy. It showed an incarcerated hernia and a chronically inflammatory gallbladder. We repositioned the hernia and performed a plastical closure of its laparotomic site. Afterwards the gallbladder was resected and an complete adhesiolysis of the bowel was made. Finally the anaesthesist inserted the CLINY Ileus Tube with a guidewire transnasally untill the terminal ileum through the stomach, duodenum and small bowel by surgical assistance. The balloon of CLINY Ileus Tube was inflated with 25ml of distilled water for 12 hours in order to block the inner bowel. An antibiotic treatment with Basocef and Clont was

performed and the patient was moved to a normal ward. The duration of the operation was 2 hours.

The post operative healing process was uncomplicated. On the 1st postoperative day, a conventional radiograph of the bowel was performed to make sure the CLINY Ileus Tube was in the correct position (picture 4). After that, blocking with balloon was released on the same day. From the 4th postoperative day, the tube was extracted by 20 to 30 cm everyday. And it was completely removed on the 8th day. The patient tolerated Enteral nutrition without complications.



Pic. 4: X-ray after splinting of the small bowel with Cliny-Ileus-Tube

On the 10th postoperative day we discharged the patient in a good general status of health and with a regular intestinal passage.

④A 63 year old female patient who was treated with a Cliny Ileus Tube

The patient was hospitalized from the February 20, 2004 to March 1, 2004 in our department of surgery.

Diagnoses:

1. **adhesion ileus, situation after appendectomy and after cholecystectomy**
2. **diverticulosis of the small bowel**
3. **diverticulosis of the sigmoid**

Our treatment:

1. **laparotomy and exploration of the abdominal cavity**
2. **extensive adhesiolysis**
3. **resection of 6 diverticula of the small bowel**
4. **intra-operative splinting of the small bowel with a CLINY Ileus Tube**

Epicrisis:

A 63 year old female patient was referred to our hospital with the clinical signs of an ileus. No defecation took place for at least 30 hours, but no nausea or vomiting either. An unspecific pain was described in the right hypogastricum. An appendectomy and a cholecystectomy were performed several years ago. On the clinical inspection, there was no muscular defence of the abdominal wall. No fever and no suspect were observed as the results of the rectal examination or the urine tests. We auscultated reduced peristaltic sounds. A conventional x-ray of the abdomen showed an ileus of the small bowel with several endoluminal surfaces.

In a three hours and 20 minutes operation, we performed an extensive adhesiolysis and atypical resections of six small bowel diverticula, which were found accidentally.

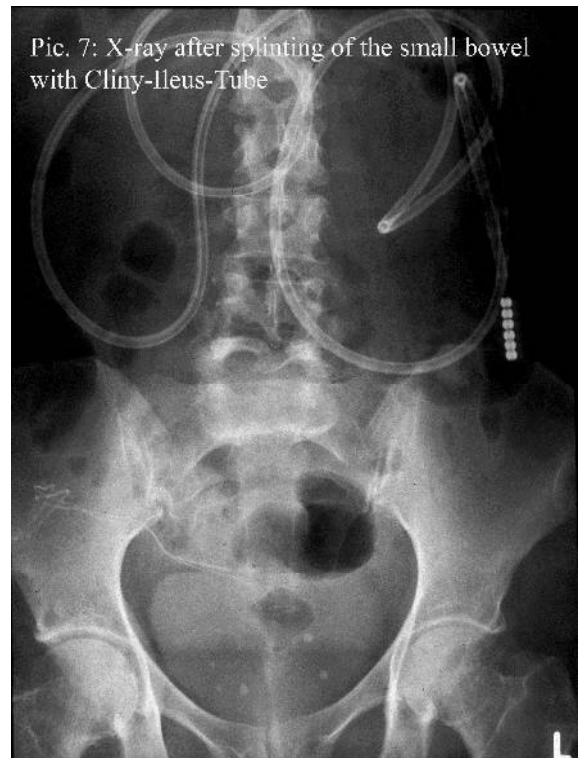
Finally the anaesthetist inserted the CLINY Ileus Tube with a guidewire transnasally until the terminal ileum through the stomach, duodenum and small bowel by surgical assistance.

The balloon of CLNY Ileus Tube was inflated with 25ml of distilled water for 12 hours in order to block the inner bowel. An antibiotic treatment with Cefazolin and Metronidazol was performed.

On the 1st postoperative day the patient was transferred to the normal ward. To evaluate the right position of the tube, an x-ray was carried (picture 7).

Afterwards the blocking was released. From the 4th postoperative day, we started the extraction of the tube by 20 cm to 30cm every day and the CLINY Ileus Tube was completely extracted on the 8th postoperative day. Then any complications did not occur and we started the enteral nutrition of the patient.

On the 10th postoperative day, we discharged the patient in a good general status of health and with a regular intestinal passage.



Pic. 7: X-ray after splinting of the small bowel with CLiny-Ileus-Tube